

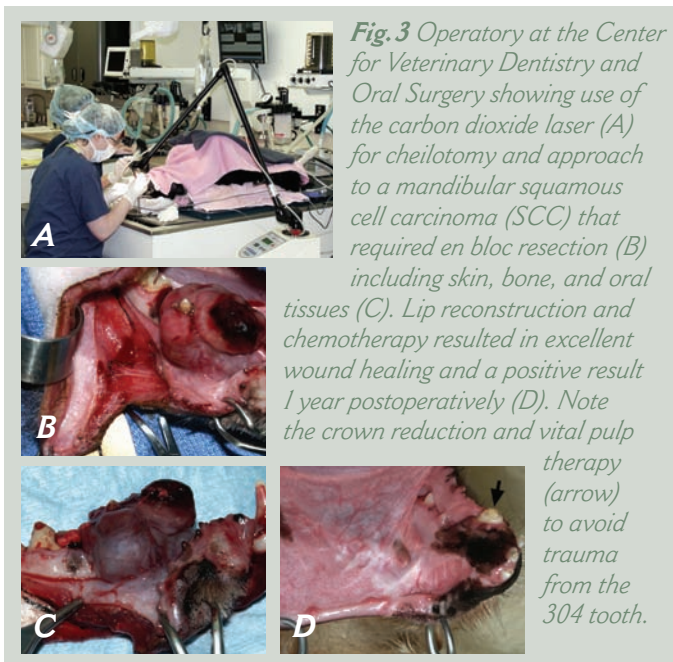
## ORAL TUMORS:

### True or False - Surgery is Almost Always Part of a Multimodality Treatment Plan for Oral Tumors.

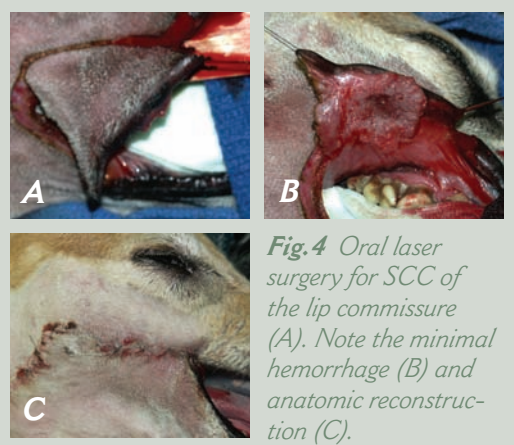
**True!** The referring clinician, oral and maxillofacial surgeon, and oncologist work as a team to stage the neoplasm: CBC, serum chemistries, thoracic radiographs +/- MRI or CT scan of the lesion, incisional or excisional biopsy, and regional lymph node (mandibular, parotid, medial retropharyngeal) excisional biopsy. Why is the staging process important? This information is valuable to the owner/surgeon/

oncologist to decide: Has the neoplasm already metastasized? Is the neoplasm potentially resectable? What is the prognosis with complete/ or incomplete excision? What type of follow-up oncologic therapy will be recommended?

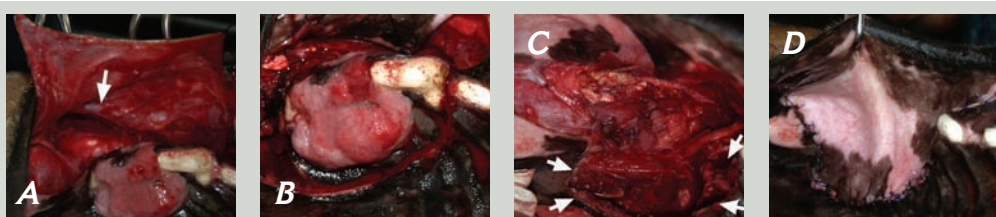
*The surgeon's operative goal is always tumor-free margins following resection. This goal often necessitates aggressive en bloc surgery with 1-2 cm gross tumor-free margins. CO2 laser surgery for soft tissue resection decreases*



postoperative pain and decreases intra-operative hemorrhage. Osteotomy of associated bone is required. In fact, since skin is usually within the margin area, cutaneous resection is often indicated (Fig. 3). Therefore, surgery may involve the hemorrhage-prone nasal cavity, or lip reconstruction (Figs. 4 and 5). Familiarity with various plastic and reconstructive surgery techniques is important since post-resection wounds may be intimidating and appear daunting to close. Intraoral lesions may require large buccal mucosal flaps or a hard palate mucoperiosteal flap based on the greater palatine artery to provide wound closure and avoid oronasal fistula as a complication (Fig. 5).



(continued on back)



*Fig. 5 Oral laser surgery for an acanthomatous epulis of the maxilla requiring a large buccal mucosal flap for closure (A) that exposed the deep facial vein (arrow). The resection approached midline (B). The nasal cavity (arrows) was involved (C) requiring a tension-free wound closure (D).*