

DISCOLORED TEETH:

True or False - Discolored Teeth are not a Problem.

False! A recent study has shown that 93% of all discolored teeth are non-vital. Teeth become discolored because of pulpitis (Fig. 1). The pulpitis is usually a result of blunt trauma that is not severe enough to cause crown fracture, but causes injury and inflammation to the tissues (pulp) that occupy the inside of the tooth. Inflammation within a fixed, rigid space without collateral circulation results in tissue necrosis. *Why does the tooth change color?* Hemosiderin pigments and the pigmented by-products of the inflammatory process leach into the dentin imparting the familiar grey-mauve-magenta coloration (Fig. 2). The tooth color does not change over time and the tooth does not seem to cause any discomfort. *So what's the fuss?* Even though the tooth does not cause pain (because it is most likely dead!), the necrotic tissue within the pulp is an excellent medium for bacterial growth. Although the tooth may appear fine

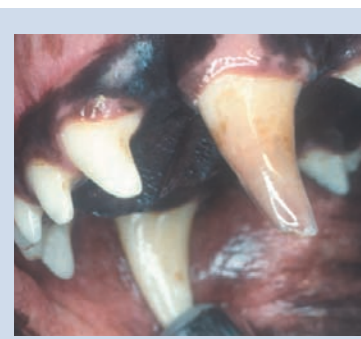

Fig. 1 Photograph of a discolored, devitalized maxillary canine tooth in a dog.

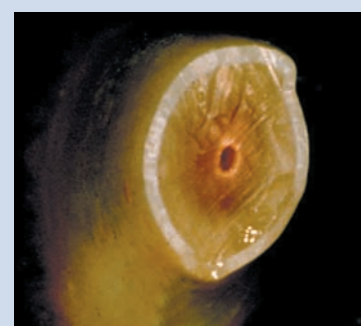


Fig. 2 Cross-section of a discolored, devitalized maxillary canine tooth in a dog showing leaching of inflammatory pigments into the dentin.

from the outside, intraoral dental radiographs (*showing the 70 % of the tooth you can't see*) will often reveal periapical infection secondary to seeding of the necrotic tissue by hematogenous bacteria; or bone destruction from the inflamed pulp (Fig. 3). The source of the bacteria could be distant (cystitis, prostatitis, nephritis) or local (bleeding gums from gingivitis).

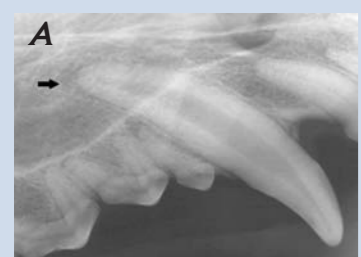

Fig. 3 Radiographs of a discolored, devitalized (A) maxillary canine tooth and the normal (B) contralateral tooth in a dog. Note the wide pulp canal and periapical radiolucent area (arrow) indicating pulp death and secondary infection/ bone resorption.

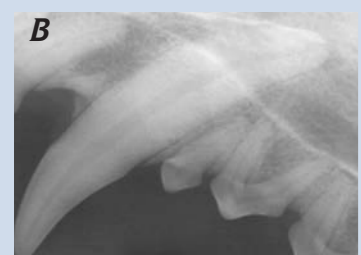

Fig. 3 Radiographs of a discolored, devitalized (A) maxillary canine tooth and the normal (B) contralateral tooth in a dog. Note the wide pulp canal and periapical radiolucent area (arrow) indicating pulp death and secondary infection/ bone resorption.

Although the tooth may appear fine from the outside, intraoral dental radiographs (*showing the 70 % of the tooth you can't see*) will often reveal periapical infection secondary to seeding of the necrotic tissue by hematogenous bacteria; or bone destruction from the inflamed pulp (Fig. 3). The source of the bacteria could be distant (cystitis, prostatitis, nephritis) or local (bleeding gums from gingivitis).

Periapical abscess can be a source of bacteremia leading to systemic illness. *All discolored teeth are candidates for either root canal therapy or extraction.* Watching and waiting is not a good idea!

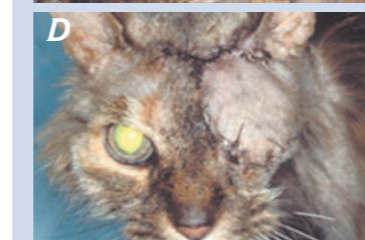
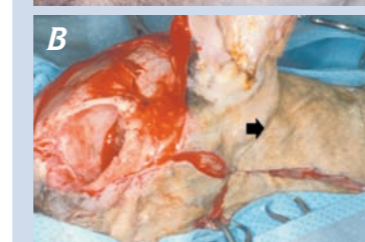
ORAL & MAXILLOFACIAL NEOPLASMS:

True or False - Initial, Aggressive Surgery Optimizes the Potential for Cure.

True! Oncologic studies in both veterinary and human medicine have shown that aggressive resective surgery as a component of a multimodality treatment plan provides the patient with the most positive prognosis. Debulking procedures and multiple more conservative surgeries are associated with decreased survival rates, not to mention having a negative impact on quality of life. Reconstructive surgical methods that provide the surgeon with techniques for wound closure provide the confidence and ability to attain greater gross tumor-free tissue margins that are directly correlated with tumor-free margins on histopathologic examination of the resected lesion. The oral and maxillofacial surgeon and oncologist work as a team to stage the neoplasm: thoracic radiographs +/- MRI, biopsy, CT scan of the lesion, regional lymph node (mandibular, parotid, medial retropharyngeal) excisional biopsy. *Why is the staging process important?* This information is valuable to the owner/surgeon/oncologist to decide: Has the neoplasm already metastasized? Is the neoplasm potentially resectable? What is the prognosis with complete/or incomplete excision? What type of follow-up oncologic therapy will be recommend?

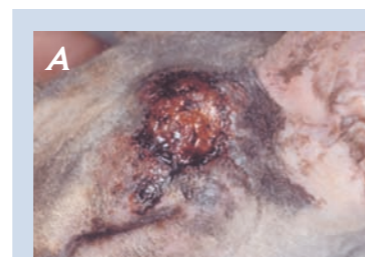

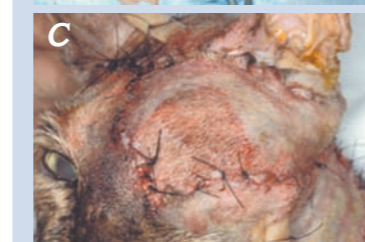Fig. 4 Photographs of a 12-year-old DSH cat with squamous cell carcinoma encroaching on the left upper eyelid (A). The lesion required orbital exenteration and reconstruction using an axial pattern flap (arrow) based on the caudal auricular artery (B). The flap provided wound coverage (C) with no wound healing complications noted 3-weeks postoperatively (D).



Have a plan! Multiple plans... A, B, and C. The staging and pre-operative planning process allows the oral and maxillofacial surgeon to design a surgical plan that may utilize regional axial pattern flaps such as the caudal auricular or superficial temporal for wound closure (Fig. 4). Intraoral lesions may require large buccal mucosal flaps or a hard palate mucoperiosteal flap based on the greater palatine artery to provide wound closure and avoid oronasal fistula as a complication.

DISCOLORED TEETH: Hale, FA. Localized intrinsic staining of teeth due to pulpitis and pulp necrosis in dogs. *J Vet Dent* 2001; 18: 14-20. ORAL & MAXILLOFACIAL NEOPLASMS: Smith MM, Payne JT, Moon ML, et al. Axial pattern flap based on the caudal auricular artery in the dog. *Am J Vet Res* 52; 1991:922-5. Smith MM, Shults S, Waldron DR, Moon ML. Platysma myocutaneous flap for head and neck reconstruction in cats. *Head & Neck* 1993; 15:433-439. Smith MM. Island mucoperiosteal flap for repair of oronasal fistula in a dog. *J Vet Dent*, 2001; 18: 140-144. Smith MM. Surgical approach for lymph node staging of oral and maxillofacial neoplasms. *J Am Anim Hosp Assoc* 1995; 31: 514-518. ORAL FRACTURE REPAIR: Kern DA, Smith MM, Grant JN, Rockhill AD. Biomechanical strength of interdental fixation for mandibular fracture in dogs. *Am J Vet Res* 54; 1993:1078-85. Kern DA, Smith MM, Stevenson S, et al. Evaluation of three fixation techniques for repair of mandibular fractures in dogs. *J Am Vet Med Assoc* 1995; 206:1883-1890. Cook WT, Smith MM, Markel MD, Grant JW. Influence of an interdental full pin on stability of an acrylic external fixator for rostral mandibular fractures in dogs. *Am J Vet Res*, 2001; 62: 576-580.

ORAL FRACTURE REPAIR:

True or False - Rigid Internal Fixation is Required for Oral Fracture Repair

False! Studies have shown that interdental wiring/acrylic and external skeletal fixation are as effective as bone plating 4-months following repair of bilateral mandibular osteotomies. Bone plating is rarely required for repair of oral fractures. Further, applying plates and screws is fraught with potential complications: drill bits or screws skewering tooth roots or the inferior alveolar artery, vein, and nerve in the mandibular canal. Fracture fragments have compromised vascular supply secondary to the traumatic incident. Open surgery to isolate and precisely align fracture fragments further compromises blood supply, risking osteomyelitis. *Why not fix the fracture without touching bone?* That's right, leave the bone alone and maximize preservation of remaining blood supply by applying the fixation to teeth. After all, aren't we trying to restore occlusion so the patient will have a comfortable bite. Sure, a muzzle would work... but, would you want your mandible to be "off" by a centimeter for the rest of your life!

The goal of fracture repair is to provide bony support for the teeth. Interdental fixation using wire and acrylic restores occlusion and avoids iatrogenic trauma to teeth while maximizing preservation of fracture fragment blood supply (Fig. 5 and 6). More invasive techniques may result in perfect fracture alignment at the expense of tooth injury and subsequent loss. It doesn't make sense to injure teeth to achieve bone healing. After all, we know that dogs and cats do remarkably well after major maxillectomies and mandibulectomies. And what if teeth are missing or left on the asphalt? An external fixator is an excellent second choice.

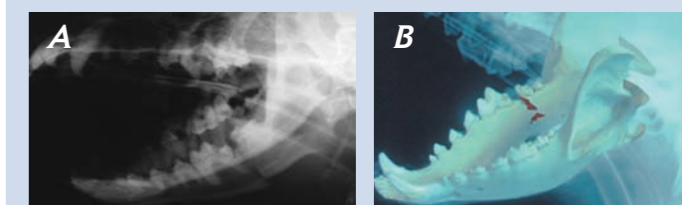


Fig. 5 Preoperative radiographic view (A) and computer-generated simulation (B) of a caudal mandible fracture in a dog.

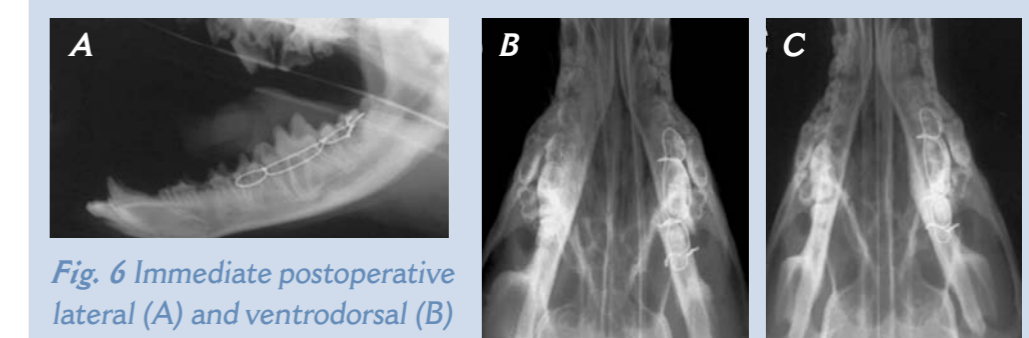


Fig. 6 Immediate postoperative lateral (A) and ventrodorsal (B) radiographs showing the result of application of interdental wire and acrylic (the acrylic is radiolucent) for mandibular fracture repair. Occlusion has been restored despite minor bone malalignment. The fracture healed without complication (C).